

## Case Report

# Pulmonary Haemorrhage in a 6-Year-Old Boy with Henoch–Schönlein Purpura

N. Besbas, A. Duzova, R. Topaloglu, F. Gok, F. Ozaltin, S. Ozen and A. Bakkaloglu  
Hacettepe University Faculty of Medicine, Ankara, Turkey

**Abstract:** Henoch–Schönlein purpura (HSP) is the most common vasculitis in children. It is a multisystemic disease but pulmonary haemorrhage is extremely rare. We present the case of a 6-year-old boy with Henoch–Schönlein purpura, pulmonary haemorrhage and severe renal involvement. The patient responded to a combination of intravenous methylprednisolone and cyclophosphamide. A review of the literature revealed that young age may be a good prognostic sign and that immunosuppressive drugs and supportive management are essential in the treatment. Renal biopsy is helpful in the differential diagnosis of HSP-mimicking pulmonary vasculitic syndromes. Combining cyclophosphamide with glucocorticoids may improve the outcome in severe HSP cases with pulmonary haemorrhage.

**Keywords:** Cyclophosphamide; Henoch–Schönlein purpura; IgA; Methylprednisolone; Pulmonary haemorrhage

## Introduction

Henoch–Schönlein purpura (HSP) is characterised by non-thrombocytopenic purpura on the lower extremities, abdominal pain, arthritis and arthralgia [1]. It is the most common vasculitis seen in children. Although renal involvement is frequent (60%), pulmonary involvement is rare and it significantly increases the mortality [2–15]. There are few reports regarding pulmonary haemorrhage in HSP. As renal biopsy was not performed in about half

of these cases, other non-IgA associated systemic vasculitis could not be excluded. The current literature is not conclusive to define the treatment of choice. This report presents a case of pulmonary haemorrhage and severe renal involvement in a 6-year-old boy with Henoch–Schönlein purpura. The patient responded to intravenous methylprednisolone and cyclophosphamide combined. We suggest that the addition of cyclophosphamide improves the outcome in severe cases with pulmonary haemorrhage.

## Case Report

In October 1998 a 6-year-old boy was admitted to a local medical centre with a complaint of purpuric rash on his lower extremities. His past and family history was unremarkable. His initial physical examination was unremarkable except for palpable purpura on the lower extremities; urinalysis and renal function were normal. One week after his initial complaints his urine output decreased; subsequently he developed oedema, hypertension, oliguria and proteinuria. His renal function had progressively deteriorated; methylprednisolone 30 mg/kg was given for 3 days before his referral to our department. The day before referral he had developed dyspnoea and his haemoglobin dropped to 4.2 g/dl; blood transfusion was given. On admission his physical examination revealed blood pressure 160/100 mmHg, temperature 37.0°C, heart rate 150/min, respiratory rate 80/min, generalised oedema, intercostal retractions with fine crackles, and the liver was palpable 7 cm below the costal margin. Initial laboratory investigations revealed haemoglobin 7.2 g/dl, WBC 10 200/mm<sup>3</sup> and platelets 450 000/mm<sup>3</sup>. The serum sodium was 142 mEq/l, potassium 4.8 mEq/l, chloride 100 mEq/l, urea nitrogen

---

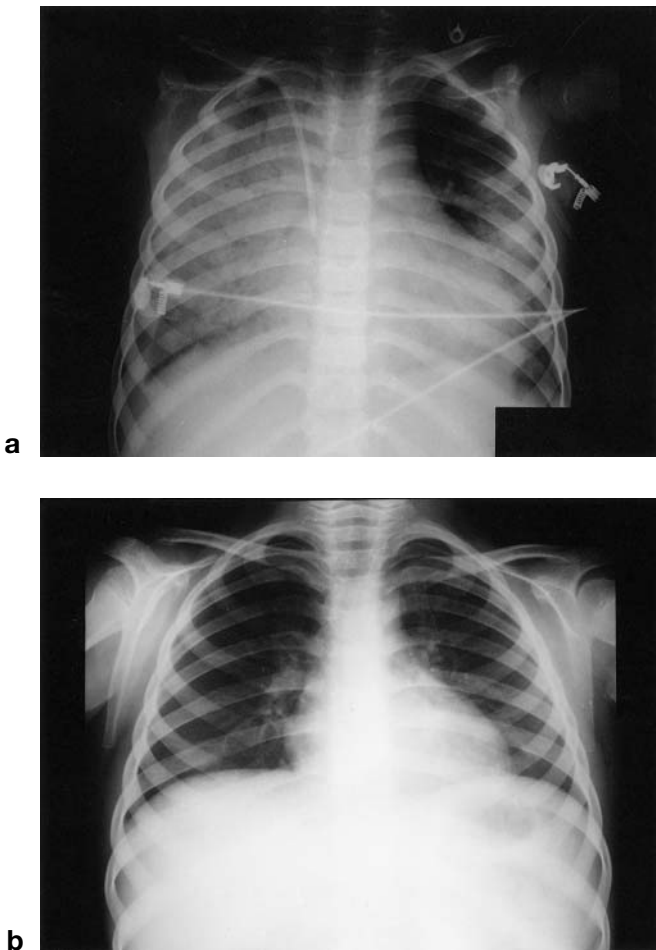
Correspondence and offprint requests to: Dr Ali Duzova, Department of Pediatrics, Pediatric Nephrology and Rheumatology Unit, Hacettepe University, Faculty of Medicine, 06100, Ankara Turkey. Tel: +90-312-311 04 64; Fax: +90-312-309 42 32; e-mail: aduzova@hun.edu.tr

72 mg/dl, creatinine 2.8 mg/dl, calcium 7.9 mg/dl, phosphorus 8.4 mg/dl, uric acid 11.5 mg/dl, total protein 5.0 g/dl, albumin 2.8 g/dl; AST and ALT values were normal. The stool was guaiac negative. Urinalysis showed a specific gravity of 1024, pH 6, proteinuria (2+) and microscopic haematuria. C3, C4, IgA, IgG and IgM values were within normal ranges; HBsAg, anti-HCV Ab, ANA, anti-dsDNA, ANCA, antiglomerular basal membrane Ab, and anticardiolipin Ab were negative; anti-HBs Ab was positive. Arterial blood gas analysis revealed hypoxaemia. Chest X-ray showed diffuse pulmonary infiltrates (Fig. 1). Although haemodialysis was instituted because of hypervolaemia and oliguria, and the fourth dose of pulse methylprednisolone (500 mg) was given, the patient required mechanical ventilation. A large amount of blood was aspirated from his endotracheal tube at the time of intubation. After a fifth dose of bolus intravenous methylprednisolone, prednisolone (2 mg/kg/day orally) was instituted. Intravenous cyclophosphamide (250 mg, single dose) was added owing to deterioration in renal function. Haemodialysis was performed every other day

for 10 days. The patient was extubated on the third day. A percutaneous kidney biopsy of 60 glomeruli showed diffuse proliferation; segmental scars and epithelial–fibroepithelial crescent formation were found in 25% and 20% of glomeruli, respectively. The immunofluorescence studies revealed heavy IgA and mild C3 and IgM staining, but not IgG in the mesangium. The patient was discharged on prednisolone (10 mg/day orally) and monthly intravenous methylprednisolone (500 mg/day for 3 days), with serum creatinine 0.3 mg/dl, proteinuria (3+) and >50 red blood cells per high-power field. Intravenous CYC was stopped as the patient experienced neutropenia lasting 4 weeks after the first intravenous dose. Nevertheless, oral cyclophosphamide (CYC, 2 mg/kg/day) was instituted at the end of the second month. By the 8th week of oral CYC the proteinuria had resolved but microscopic haematuria persisted for an additional 3 months. The patient was still in complete remission after a follow-up period of 18 months.

## Discussion

Vasculitic processes can involve the lungs. In Wegener's granulomatosis (WG) and Churg–Strauss syndrome (CSS) the lungs are affected in 70%–90% of cases [16,17]. Although rare, giant cell arteritis, Takayasu's arteritis and Behçet's disease can also cause pulmonary manifestations [18]. Diffuse pulmonary haemorrhage can be secondary to microscopic polyangiitis, WG, CSS, Behçet's disease, HSP, HBV and HCV-associated vasculitis, malignancies, drugs, systemic lupus erythematosus, antiphospholipid antibody syndrome, polymyositis, IgA nephropathy, rheumatoid arthritis, Sjögren's syndrome, Goodpasture's syndrome and bone marrow transplantation [18]. In our unit more than 550 cases of HSP have been followed; 42% had renal involvement, but we had not encountered pulmonary haemorrhage with HSP in our series. Chaussain et al. [19] showed impairment of lung diffusion capacity to be a common finding in children with HSP, but pulmonary haemorrhage in Henoch–Schönlein purpura is extremely rare: a total of 20 cases with an age range between 4.5 and 78 years have been reported [2–16]. Eleven cases were seen in childhood (4.5–17 years). Because HSP mainly occurs in prepubertal children, the fact that about half of the patients presenting with pulmonary haemorrhage were adolescent or adult suggest that the older age can be a risk factor. Kidney biopsy was not available in all cases; IgA deposits were shown only in three out of nine adult cases [5,7,11] and four out of 11 childhood cases (age 7–17 years) [8,10,12,15]. In adult patients the mortality is higher than in children (Table 1). None of the five children with IgA deposits shown on renal biopsy had died. Older age and the absence of IgA deposits resulted in poor outcome. Although it is well known that IgA deposits can be negative in 10%–25% of



**Fig. 1.** Chest radiographs showing (a) diffuse bilateral infiltrates with pleural effusion and (b) normal findings on day 4 of cyclophosphamide therapy.

**Table 1.** Mortality rates according to biopsy findings and treatment modalities

	Pred	Pred + Aza	Pred + MP	MP	Pred + CYC	All
<b>Childhood</b>						
With IgA deposit	–	–	–/1 [12]	–/1 [16]	–/3 [8,10] <sup>§</sup>	–/5
Without IgA deposit*	1/1 [3]	–/1 [6]	2/4 [4,10,14]	–	–/1 [10]	3/7
Total	1/1	–/1	2/5	–/1	–/4	3/12
<b>Adult<sup>†</sup></b>						
With IgA deposit	1/2 [5,7]	–	–	1/1 [11]	–	2/3
Without IgA deposit*		1 case not treated [9] (excluded), one case [2] treated with steroid; both died				1/1

Pred, prednisolone; Aza, azathioprine; MP, methylprednisolone; CYC, cyclophosphamide.

\* Either biopsy was not done, or IgA deposit was not shown.

<sup>†</sup> Data concerning treatment and outcome of four patients were not available.

<sup>§</sup> Including our case.

cases with HSP [20,21], some cases in the non-IgA group were probably vasculitic syndromes mimicking HSP.

Of the childhood cases all but one had proteinuria and haematuria; renal failure was seen in two cases (one patient with IgA desposits) (Table 1). The patient reported here is the fifth and the youngest 'well-defined HSP' with pulmonary haemorrhage during childhood. He is also the youngest (6 years, versus 7–17 years). Our patient had severe renal involvement and severe respiratory distress secondary to pulmonary haemorrhage. Although lung biopsy was not performed, lung tissue was probably severely involved. Intra-alveolar haemorrhage, leukocytoclastic vasculitis and interstitial pneumonitis are common histological findings of pulmonary involvement in HSP [2,9,11,12].

Prednisolone and methylprednisolone were used either alone or in combination with cyclophosphamide and azathioprine (Table 1). Early reports concerning steroid treatment were discouraging [2–5]. Olson [10] had suggested that steroids plus cyclophosphamide should be the treatment of choice. Recently Vats et al. [15] reported a 7-year-old boy with pulmonary haemorrhage (without renal failure) who responded to intravenous methylprednisolone followed by oral prednisolone; the patient was extubated on day 14. The addition of cyclophosphamide might have shortened the period of mechanical ventilation in our case (3 days). It is striking that in childhood none of the four patients treated with prednisolone and CYC had died, compared to three of eight patients (37.5%) treated with other drugs but not CYC. On the other hand, one should be aware of acute and late side effects of CYC; our patient experienced neutropenia lasting 4 weeks without any serious infection.

More 'well-defined HSP' patients with pulmonary haemorrhage should be studied to determine risk factors, probable subgroups and prognostic factors, and to compare treatment modalities. Aggressive supportive treatment and steroids plus CYC are the treatment of choice in such severe cases.

## References

- Cassidy JT, Petty RE. Textbook of pediatric rheumatology, 2nd edn. New York: Churchill Livingstone, 1990:394–8.
- Jacome AF. Pulmonary haemorrhage and death complicating anaphylactoid purpura. *South Med J* 1967;60:1003–4.
- Weiss VF, Naidu S. Fatal pulmonary haemorrhage in Henoch–Schönlein purpura. *Cutis* 1979;23:687–8.
- Marandian MH, Ezzati M, Behvad A, Mozzami P, Rakhchan M. Manifestations pulmonaires du purpura rhumatoïde de Schönlein–Henoch chez un enfant de huit ans. *Arch Fr Pediatr* 1982;39:255–7.
- Kathuria S, Chief G. Fatal Henoch–Schönlein syndrome. *Chest* 1982;82:654–6.
- Leatherman JW, Sibley RK, Davies SF. Diffuse intrapulmonary haemorrhage unrelated to anti-glomerular basement membrane antibody. *Am J Med* 1982;72:401–10.
- Scichiri M, Tsutsumi K, Yamamoto I, Ida T, Ivamoto H. Diffuse pulmonary haemorrhage and renal failure in adult Henoch–Schönlein purpura. *Am J Nephrol* 1987;7:140–2.
- Payton CD, Allison ME, Boulton-Jones JM. Henoch–Schönlein purpura presenting with pulmonary haemorrhage. *Scott Med J* 1987;32:26–7.
- Markus HS, Clark JV. Pulmonary haemorrhage in Henoch–Schönlein purpura. *Thorax* 1989;44:525–6.
- Olson JC, Kelly KJ, Pan CG, Wortmann DW. Pulmonary disease with haemorrhage in Henoch–Schönlein purpura. *Pediatrics* 1992;89:1177–81.
- Yokose T, Aida J, Ito Y, Ogura M, Nakagawa S, Nagai T. A case of pulmonary haemorrhage in Henoch–Schönlein purpura accompanied by polyarteritis nodosa in an elderly man. *Respiration* 1993;60:307–10.
- Wright WK, Krous HF, Grisvodl WR et al. Pulmonary vasculitis with haemorrhage in anaphylactoid purpura. *Pediatr Pulmonol* 1994;17:269–71.
- Carter ER, Guevara JP, Moffitt DR. Pulmonary haemorrhage in an adolescent with Henoch–Schönlein purpura. *West J Med* 1996;164:171–3.
- Paller AS, Kelly K, Sethi R. Pulmonary haemorrhage: an often-fatal complication of Henoch–Schönlein purpura. *Pediatr Dermatol* 1997;14:299–302.
- Vats KR, Vats A, Kim Youngki, Dassenko D, Sinaiko A. Henoch–Schönlein purpura and pulmonary haemorrhage: a report and literature review. *Pediatr Nephrol* 1999;13:530–4.
- Hoffman GS, Kerr GS, Leavitt RY et al. Wegener granulomatosis: An analysis of 158 patients. *Ann Intern Med* 1992;116:488–98.
- Hoffman GS, Kerr GS. Recognition of systemic vasculitis in acutely ill patient. In: Mandell BF, ed. *Acute rheumatic and immunologic diseases*. New York: Marcel-Dekker, 1994:279–307.

18. Sullivan EJ, Hoffman G. Pulmonary vasculitis. *Clin Chest Med* 1998;4:759–76.
19. Chaussain M, Boissieu D de, Kalifa G et al. Impairment of lung diffusion capacity in Henoch–Schönlein purpura. *J Pediatr* 1992;121:12–16.
20. Counahan R, Cameron JS. Henoch–Schönlein nephritis. *Contrib Nephrol* 1977;7:143–65.
21. Van Hale HM, Gibson LE, Schroter AL. Henoch–Schönlein vasculitis: direct immunofluorescence study of uninvolved skin. *J Am Acad Dermatol* 1986;15:665–70.

*Received for publication 5 July 2000  
Accepted in revised form 2 February 2001*