

see commentary on page 980

Recessive missense mutations in *LAMB2* expand the clinical spectrum of *LAMB2*-associated disorders

K Hasselbacher^{1,2}, RC Wiggins³, V Matejas⁴, BG Hinkes¹, B Mucha¹, BE Hoskins¹, F Ozaltin^{1,5}, G Nürnberg⁶, C Becker⁶, D Hangan¹, M Pohl⁷, E Kuwertz-Bröking⁸, M Griebel⁹, V Schumacher¹⁰, B Royer-Pokora¹⁰, A Bakkaloglu⁵, P Nürnberg⁶, M Zenker⁴ and F Hildebrandt¹

¹Departments of Pediatrics and of Human Genetics, University of Michigan, Ann Arbor, Michigan, USA; ²Division of Nephrology, University of Erlangen-Nuremberg, Erlangen-Nuremberg, Germany; ³Department of Internal Medicine, University of Michigan, Ann Arbor, Michigan, USA; ⁴Institute of Human Genetics, University of Erlangen-Nuremberg, Erlangen-Nuremberg, Germany; ⁵Department of Pediatric Nephrology, Hacettepe University Faculty of Medicine, Ankara, Turkey; ⁶Cologne Center for Genomics (CCG) and Institute for Genetics, University of Cologne, Cologne, Germany; ⁷Department of Pediatric and Adolescent Medicine, University of Freiburg, Freiburg, Germany; ⁸Department of Pediatric Nephrology, University of Muenster, Muenster, Germany; ⁹Department of Pediatric Nephrology, Technical University of Munich, Munich, Germany and ¹⁰Institute of Human Genetics, University of Duesseldorf, Duesseldorf, Germany

Congenital nephrotic syndrome is clinically and genetically heterogeneous. The majority of cases can be attributed to mutations in the genes *NPHS1*, *NPHS2*, and *WT1*. By homozygosity mapping in a consanguineous family with isolated congenital nephrotic syndrome, we identified a potential candidate region on chromosome 3p. The *LAMB2* gene, which was recently reported as mutated in Pierson syndrome (microcoria-congenital nephrosis syndrome; OMIM #609049), was located in the linkage interval. Sequencing of all coding exons of *LAMB2* revealed a novel homozygous missense mutation (R246Q) in both affected children. A different mutation at this codon (R246W), which is highly conserved through evolution, has recently been reported as causing Pierson syndrome. Subsequent *LAMB2* mutational screening in six additional families with congenital nephrotic syndrome revealed compound heterozygosity for two novel missense mutations in one family with additional nonspecific ocular anomalies. These findings demonstrate that the spectrum of *LAMB2*-associated disorders is broader than previously anticipated and includes congenital nephrotic syndrome without eye anomalies or with minor ocular changes different from those observed in Pierson syndrome. This phenotypic variability likely reflects specific genotypes. We conclude that mutational analysis in *LAMB2* should be considered in congenital nephrotic syndrome, if no mutations are found in *NPHS1*, *NPHS2*, or *WT1*.

Kidney International (2006) **70**, 1008–1012. doi:10.1038/sj.ki.5001679; published online 16 August 2006

KEYWORDS: nephrotic syndrome; Pierson syndrome; *LAMB2*; autosomal recessive

Correspondence: F Hildebrandt, Departments of Pediatrics and of Human Genetics, University of Michigan Health System, 8220C MSRB III, 1150 West Medical Center Drive, Ann Arbor, Michigan 48109-0646, USA.
E-mail: fhilde@umich.edu

Received 6 April 2006; revised 17 May 2006; accepted 23 May 2006; published online 16 August 2006

Congenital nephrotic syndrome is a heterogeneous disorder characterized by proteinuria with consecutive edema starting *in utero* or within the first 3 months of life.¹ *NPHS1* and *NPHS2* mutations are known to be associated with autosomal recessive isolated nephrosis.^{2,3} The respective gene products nephrin and podocin are interacting transmembrane proteins at the glomerular slit diaphragm.^{4,5} Specific heterozygous mutations in *WT1*, a zinc-finger transcription factor, can cause Denys–Drash syndrome, Frasier syndrome, or isolated diffuse mesangial sclerosis.⁶ We have recently shown in a worldwide cohort of 48 patients with nephrotic syndrome within the first year of life that mutations in *NPHS1*, *NPHS2*, and *WT1* account for 44, 44, and 5% of cases, respectively.⁷ Still, in some cases with isolated congenital nephrotic syndrome and in the majority of patients with syndromic forms associated with neurological, ocular, skeletal, and other abnormalities,¹ the genetic basis remains unclear. Recently, mutations in the *LAMB2* gene were described by Zenker *et al.*^{8,9} as a cause underlying Pierson syndrome (microcoria-congenital nephrosis syndrome; OMIM #609049), denoting an entity characterized by congenital nephrotic syndrome and a complex ocular maldevelopment with non-reactive narrowing of the pupils (microcoria) as the prominent clinical finding.¹⁰ Herein, we report for the first time on *LAMB2* mutations in patients with much milder disease, based on the initial observation of linkage to the *LAMB2* locus in a consanguineous family (F1012) with isolated congenital nephrotic syndrome. The findings emphasize that *LAMB2* mutations should be considered in molecular genetic diagnostics of early onset nephrotic syndrome.

RESULTS

We identified a consanguineous family (F1012) with two children affected by congenital nephrotic syndrome. Both developed proteinuria before the age of 3 months and

end-stage renal failure within the first year of life. Kidney biopsy of the first child (F1012 II-1) showed focal and segmental glomerulosclerosis with abnormalities of the glomerular basement membrane. This girl died of pneumonia after kidney transplantation at the age of 5 years. No biopsy has been performed in her younger affected brother (F1012 II-2), who is currently 3 years old. Except for their renal disease, both children displayed no other primary abnormalities. Their psychomotor development was normal. Neurological and ophthalmological investigations, including ophthalmoscopy revealed no abnormalities in either sibling. No mutations in *NPHS1*, *NPHS2*, and *WT1* were found. Homozygosity mapping of family F1012 yielded four regions of probable homozygosity by descent. These were confirmed and refined by typing of polymorphic microsatellite markers, yielding potential candidate regions on chromosome 3, 4, 10, and 12 with segments of homozygosity of ~12, ~1, ~37, and ~2 Mb, respectively. The region of interest on chromosome 3 (Figure 1) contained *LAMB2*, the gene encoding laminin $\beta 2$, which has been implicated in nephrotic syndrome in the *LAMB2* knockout mouse model as well as in Pierson syndrome in humans.^{8,11} Mutational screening of *LAMB2* revealed a homozygous missense mutation c.737G>A in both affected children (F1012 II-1, II-2). This mutation predicts a substitution of a highly conserved arginine residue R246Q (Figure 2; Table 1).

Six additional unrelated families (F797, F1234, F1379, A141, A816, A931) with one or more children affected by congenital nephrotic syndrome, who had previously been tested negative for mutations in *NPHS1*, *NPHS2*, and *WT1* were subsequently examined by mutational analysis of *LAMB2*. There was isolated kidney involvement in five families and association with nonspecific eye abnormalities in one. *LAMB2* mutations were identified only in family F1234.

In this family, the first affected child (II-1) was noted to have congenital nystagmus with a hypopigmented fundus, strabismus, and myopia. By the age of 3 years, the fundus hypopigmentation disappeared, whereas high-grade myopia (diopter 8) persisted with nystagmus and strabismus being only apparent without corrective lenses. The affected male sibling (II-2), who was 9 months of age at the last follow-up, has congenital nephrotic syndrome associated with a hypopigmented retina, but no nystagmus or refractive error was evident by that age. Only he was also noted to have mild narrowing of the pupils. Kidney biopsy of the elder sister (II-1) showed glomerular minimal lesions with augmentation and vacuolation of podocytes and broadened lamina rara. Both children progressed to end-stage renal failure within the first year of life. Their neurological and cognitive development was normal. Both affected children harbored three heterozygous sequence variations: two nucleotide substitutions c.4140C>A and c.4177C>T, predicting amino-acid exchanges N1380K and L1393F, respectively, which turned out to be located on the same, maternally inherited allele, and one paternally inherited point mutation c.961T>C resulting

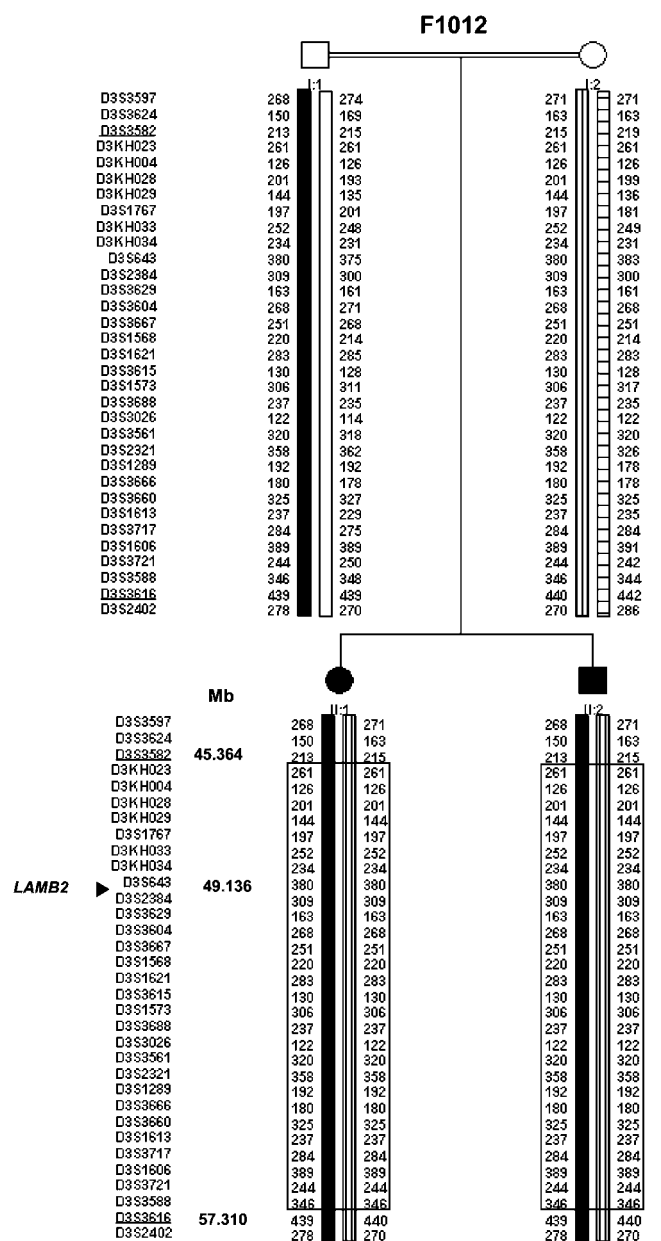


Figure 1 | Refinement of the *LAMB2* gene locus by haplotype analysis in the consanguineous congenital nephrotic syndrome family F1012. Thirty-three microsatellite markers on chromosome 3p are shown on the left from p-ter to cen (top to bottom). Haplotypes are interpreted in differently shaded bars. Paternal haplotypes are drawn to the left, maternal ones to the right. The frame depicts the extent of homozygosity by descent. Physical map positions (Mb) are given for the flanking markers (underlined) and the candidate gene *LAMB2* (as annotated by GenomeBrowser; <http://genome.ucsc.edu>). Flanking markers (underlined) are defined through lack of homozygosity in individuals II:1 and II:2 and delimit a 11.9 Mb critical genetic interval for this chromosome 3 locus.

in C321R. L1393 and C321 represent highly conserved residues (Figure 2c).

All changes were not detected in at least 160 matched control chromosomes from the respective ethnical group (Turkish or Caucasian).

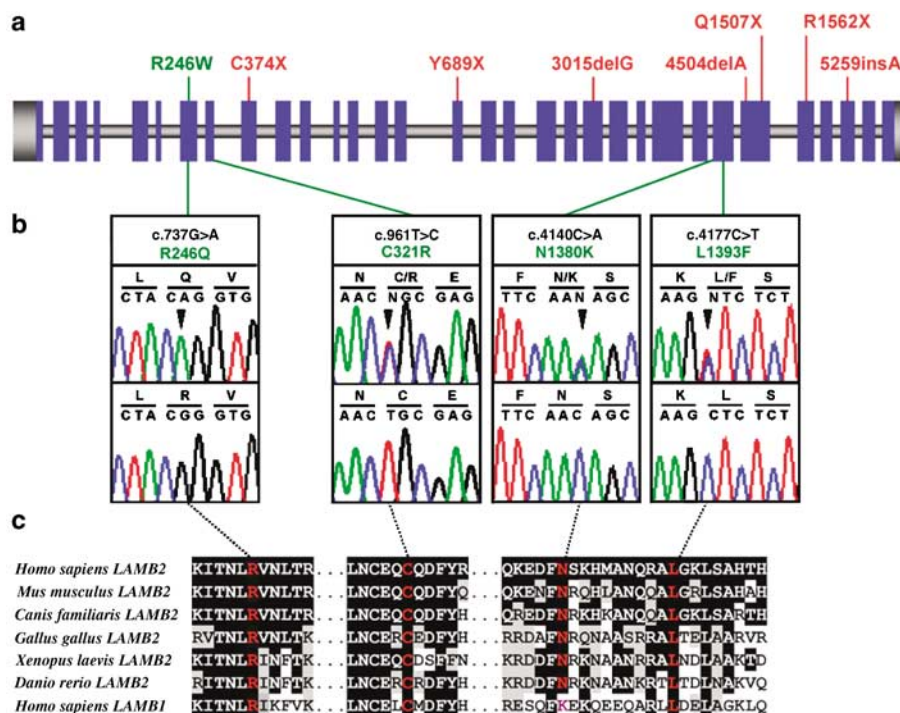


Figure 2 | Position of mutations in the LAMB2 gene. (a) Exon–intron structure of LAMB2 showing the position of previously published mutations in Pierson syndrome above the gene. Truncating mutations are shown in red; missense mutations in green. (b) Four different missense variants were detected in two families with congenital nephrotic syndrome (see also Table 1). Sequence traces are shown for affected individuals (top) and healthy controls (bottom). The R246Q mutation was present in individuals F1012 II-1 and II-2 in the homozygous state, whereas the C321R, N1380K, and L1393F sequence variants were present in patients F1234 II-1 and II-2 in the heterozygous state. (c) Alignment of LAMB2 sequences with lower organisms shows a high level of evolutionary conservation of mutated residues. For sequence variant, N1380K alignment of human homologs LAMB2 and LAMB1 shows substitution of N1380 by K1380.

Table 1 | LAMB2 mutations and clinical presentation in two unrelated families with congenital nephrotic syndrome

Family (individual)	Ethnic origin	Nucleotide alteration(s) ^a	Alteration(s) in coding sequence	Exon (segregation) ^b	Parental consanguinity	Onset of congenital nephrotic syndrome	Extrarenal manifestation
F1012 (II-1) (II-2)	Turkish	c.737G>A	R246Q	7 (hom, M, P)	+	1 month after birth	None
		c.737G>A	R246Q	7 (hom, M, P)			
F1234 (II-1) (II-2)	German-Caucasian	c.961T>C	C321R	8 (het, P)	–	3 months	Nystagmus, myopia, strabismus
		c.4140C>A and c.4177C>T	N1380K and L1393F	26 and 26 (het, M)			
		c.961T>C	C321R	8 (het, P)			
		c.4140C>A and c.4177C>T	N1380K and L1393F	26 and 26 (het, M)			

^aAll mutations were absent from at least 160 healthy control subjects.

^bHet, heterozygous in affected individual; hom, homozygous in affected individual; M, mutation identified in mother; P, mutation identified in father.

DISCUSSION

LAMB2 mutations were previously found to be consistently associated with the severe phenotype of Pierson syndrome, which is characterized by congenital nephrotic syndrome with diffuse mesangial sclerosis and early onset renal failure, as well as distinct ocular malformations including microcoria, abnormal lens shape with cataracts, and retinal abnormalities.^{8–10,12} In addition, children with Pierson syndrome who survived infancy exhibited severe neurodevelopmental deficits and blindness.⁸ This report expands the

spectrum of LAMB2-associated disorders to congenital nephrotic syndrome with milder ocular changes (F1234) and normal development, and even to isolated congenital nephrotic syndrome (F1012). Ocular abnormalities in family F1234 included myopia, fundus abnormality, and nystagmus, whereas pupillary anomalies, previously regarded as the hallmark of Pierson syndrome, were only mildly present in one of the two affected children (II-1). None of the patients reported here had cataracts or severe impairment of visual function as seen in Pierson syndrome. Remarkably, the

association of congenital nephrotic syndrome and nystagmus with retinal abnormalities was reported previously as a distinct entity,¹³ listed in the OMIM database as ‘mesangial sclerosis, diffuse renal, with ocular abnormalities’ (OMIM #249660). Presence of nystagmus has also been reported occasionally in other patient cohorts with congenital nephrotic syndrome.^{1,14} The patients presented here also had a slower progression to renal failure and less severe changes on kidney biopsies compared to Pierson syndrome. Our findings suggest that this condition might represent a milder allelic variant of Pierson syndrome.

This view is supported by the strong predominance of biallelic-truncating *LAMB2* mutations with complete lack of laminin $\beta 2$ in patients with the typical Pierson phenotype,^{8,9} in contrast to the missense changes demonstrated here, that may represent hypomorphic alleles. Only two previously reported siblings¹⁵ had a missense mutation of *LAMB2* (R246W), and they also displayed a somewhat milder clinical course in that they did not experience end-stage renal failure before the age of 6 months. Residual laminin $\beta 2$ expression was shown in kidney tissue of one of these children.⁸

Although no functional studies have been performed, the amino-acid changes R246Q, C321R, and L1393F are very likely to be causative mutations, based on formal criteria (evolutionary conservation, absence in healthy controls, segregation of the mutations with the phenotype). R246Q affects the same highly conserved residue as the R246W mutation that has been reported to cause Pierson syndrome and be associated with markedly reduced expression of *LAMB2*.⁸ R246 is located within the N-terminal domain VI, which mediates the polymerization of laminin heterotrimers.¹⁶ We speculate that substitution of this residue perturbs this process to varying degrees, depending on the nature of the mutant residue at this position, with tryptophan having a more deleterious effect than glutamine. C321, which belongs to the first of 13 laminin-type epidermal growth factor-like motifs of the laminin $\beta 2$ protein is likely involved in an intramolecular disulfide bond with C312 (Swiss-Prot: locus *LAMB2_HUMAN*, accession no. P55268). Moreover, substitution of the corresponding amino acid, C293, in the human paralog laminin $\beta 3$ has been identified as a cause of junctional epidermolysis bullosa.¹⁷ L1393 is located within domain II, which is particularly rich in hydrophobic side chains and forms a coiled-coil structure to which all three chains of the cross-shaped laminin heterotrimer contribute. Mutation of this residue may perturb the assembly of the triple helical structure of laminin heterotrimers. L1393F is more likely than N1380K to be the causative maternal mutation in family F1234 as N1380 is substituted by K1380 in human *LAMB1*.

The clinical and molecular findings presented here clearly indicate genotype-phenotype correlations among patients with *LAMB2* mutations: homozygosity or compound heterozygosity for mutations conferring complete loss-of-function (e.g. truncating mutations) appear to be consistently

associated with the typical features of Pierson syndrome, including neonatal renal failure, severe ocular abnormalities, and neurological impairment in long-term survivors. In contrast, patients with non-truncating (missense) *LAMB2* mutations may display variable phenotypes ranging from a milder variant of Pierson syndrome (as observed with the R246W mutation) to isolated congenital nephrotic syndrome (as reported herein with the R246Q mutation). A syndrome comprising congenital nephrotic syndrome and ocular anomalies with nystagmus and nonspecific fundus irregularities (OMIM #249660) may represent an intermediate phenotype among the $\beta 2$ lamininopathies. We conclude that *LAMB2* mutational screening should be considered in any case of congenital nephrotic syndrome, particularly in the presence of ocular abnormalities of any kind, but also in isolated congenital nephrotic syndrome if no mutations have been found in *NPHS1*, *NPHS2*, or *WT1*.

MATERIALS AND METHODS

We obtained blood samples for DNA extraction and clinical data following informed parental consent. Ethics committee approval was obtained from the ethics committee of the University of Freiburg (Freiburg, Germany) and the Internal Review Board of the University of Michigan (IRBMED, Ann Arbor, MI, USA). The clinical diagnosis of congenital nephrotic syndrome was established by nephrologists from different pediatric nephrology centers according to published criteria.¹⁸ For clinical evaluation, we used a standard questionnaire as described previously.¹⁹ All patients included in this study were specifically examined by ophthalmologists. In addition, neurological status, cognitive function, and development were documented according to the regular German screening program in standardized clinical examinations at 0.25, 0.5, 1, 2, 4, and 6 years of age.

Whole genome linkage scans were performed using a 10K single nucleotide polymorphism hybridization array (Affymetrix, Santa Clara, CA, USA). Multipoint lod scores were calculated using the Genehunter program v2.1_r3.²⁰ Further genotyping was achieved by analyzing polymorphic microsatellites markers generated from the public human genome sequence. Markers were analyzed on an ABI Prism[®] 3100-Avant Genetic Analyzer (Applied Biosystems, Foster City, CA, USA). Primer sequences are available on request. Mutational analysis of *LAMB2* was performed by bidirectional sequencing of all 32 exons of the gene including the flanking intronic regions as described previously.⁸

ACKNOWLEDGMENTS

We sincerely thank the patients and their families for participation. We acknowledge Robert Lyons for excellent large-scale sequencing, Angelika Diem for technical assistance. We are grateful to Monika Bulla, Münster (Germany) for contribution of materials and clinical data from patients. This research was supported by grants from National Institutes of Health to FH (DK 039255-16), NKF Michigan (382235), the German National Genome Research Network to PN (01GR0416), and the Smokler Foundation. FH is the Frederick GL Huetwell Professor for the Cure and Prevention of Birth Defects, University of Michigan.

ELECTRONIC DATABASE INFORMATION

Online Mendelian Inheritance in Man (OMIM) is available at <http://www.ncbi.nlm.nih.gov>. The amino-acid sequence alignment tool used is available at <http://zeon.well.ox.ac.uk/git-bin/clustalw.cgi>.

We retrieved the sequence and exon-intron boundaries of the *LAMB2* gene from the University of California, Santa Cruz (<http://genome.uscs.edu/> Freeze May 2004).

NOTES

In the meantime, both patients of family F1234 have developed severe unilateral retinal detachment.

REFERENCES

- Habib R. Nephrotic syndrome in the 1st year of life. *Pediatr Nephrol* 1993; **7**: 347–353.
- Kestila M, Lenkkeri U, Mannikko M *et al.* Positionally cloned gene for a novel glomerular protein nephrin is mutated in congenital nephrotic syndrome. *Mol Cell* 1998; **1**: 575–582.
- Boute N, Gribouval O, Roselli S *et al.* *NPHS2*, encoding the glomerular protein podocin, is mutated in autosomal recessive steroid-resistant nephrotic syndrome. *Nat Genet* 2000; **24**: 349–354.
- Somlo S, Mundel P. Getting a foothold in nephrotic syndrome. *Nat Genet* 2000; **24**: 333–335.
- Huber TB, Simons M, Hartleben B *et al.* Molecular basis of the functional podocin–nephrin complex: Mutations in the *NPHS2* gene disrupt nephrin targeting to lipid raft microdomains. *Hum Mol Genet* 2003; **12**: 3397–3405.
- Jeanpierre C, Denamur E, Henry I *et al.* Identification of constitutional *WT1* mutations, in patients with isolated diffuse mesangial sclerosis, and analysis of genotype/phenotype correlations by use of a computerized mutation database. *Am J Hum Genet* 1998; **62**: 824–833.
- Mucha B, Hinkes B, Ozaltin F *et al.* Congenital nephrotic syndrome is primarily caused by mutations in nephrin, podocin and *WT1*. *J Am Soc Nephrol* 2005; **16**: 365A.
- Zenker M, Aigner T, Wendler O *et al.* Human laminin $\beta 2$ deficiency causes congenital nephrosis with mesangial sclerosis and distinct eye abnormalities. *Hum Mol Genet* 2004; **13**: 2625–2632.
- Zenker M, Pierson M, Jonveaux P *et al.* Demonstration of two novel *LAMB2* mutations in the original Pierson syndrome family reported 42 years ago. *Am J Med Genet* 2005; **138A**: 73–74.
- Zenker M, Tralau T, Lennert T *et al.* Congenital nephrosis, mesangial sclerosis, and distinct eye abnormalities with microcoria: An autosomal recessive syndrome. *Am J Med Genet* 2004; **130A**: 138–145.
- Noakes PG, Miner JH, Gautam M *et al.* The renal glomerulus of mice lacking s-laminin/laminin $\beta 2$: nephrosis despite molecular compensation by laminin $\beta 1$. *Nat Genet* 1995; **10**: 400–406.
- Pierson M, Cordier J, Hervouet F *et al.* Une curieuse association malformative congenitale et familiale atteignant l'oeil et le rein. *J Genet Hum* 1963; **12**: 184–213.
- Barakat AY, Allam CK, Najjar SS. Diffuse mesangial sclerosis and ocular abnormalities in two siblings. *Int J Pediatr Nephrol* 1982; **3**: 33–35.
- Martul EV, Cuesta MG, Churg I. Histopathologic variability of the congenital nephrotic syndrome. *Clin Nephrol* 1987; **28**: 161–168.
- Glastre C, Cochat P, Bouvier R *et al.* Familial infantile nephrotic syndrome with ocular abnormalities. *Pediatr Nephrol* 1990; **4**: 340–342.
- Colognato H, Winkelmann AD, Yurchenco PD. Laminin polymerization induces a receptor–cytoskeleton network. *J Cell Biol* 1999; **145**: 619–631.
- Pulkkinen I, Jonkman MF, McGrath JA *et al.* *LAMB3* mutations in generalized atrophic benign epidermolysis bullosa: consequences at the mRNA and protein levels. *Lab Invest* 1998; **78**: 859–867.
- APN 1988 Arbeitsgemeinschaft für Pädiatrische Nephrologie. Short versus standard prednisone therapy for initial treatment of idiopathic nephrotic syndrome in children. *Lancet* 1988; **1**: 380–383.
- Karle SM, Uetz B, Ronner V *et al.* Novel mutations in *NPHS2* detected in both familial and sporadic steroid-resistant nephrotic syndrome. *J Am Soc Nephrol* 2002; **13**: 388–393.
- Kruglyak L, Daly MJ, Reeve-Daly MP *et al.* Parametric and non-parametric linkage analysis: a unifying multipoint approach. *Am J Hum Genet* 1996; **58**: 1347–1363.